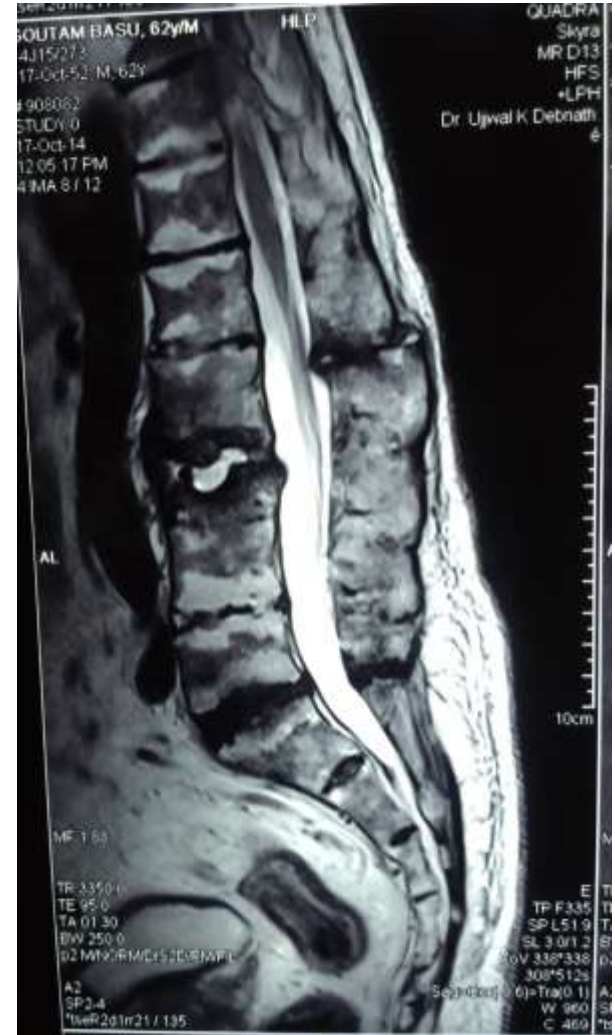
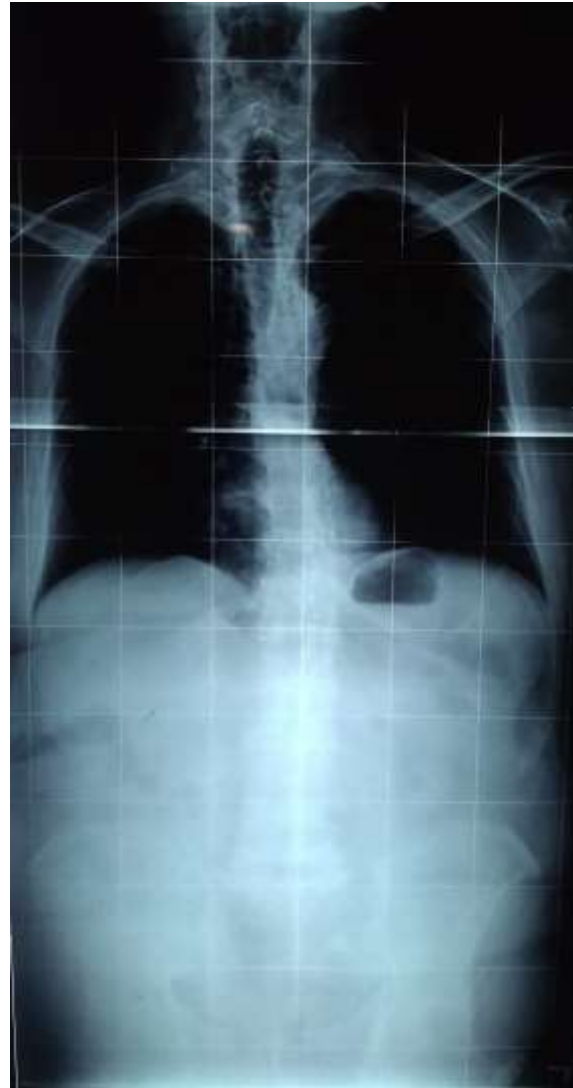
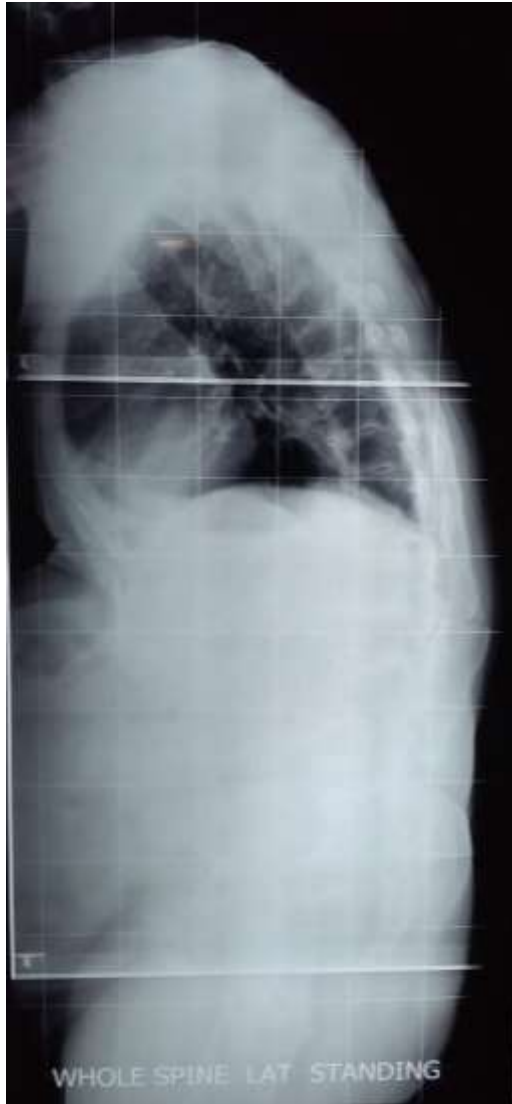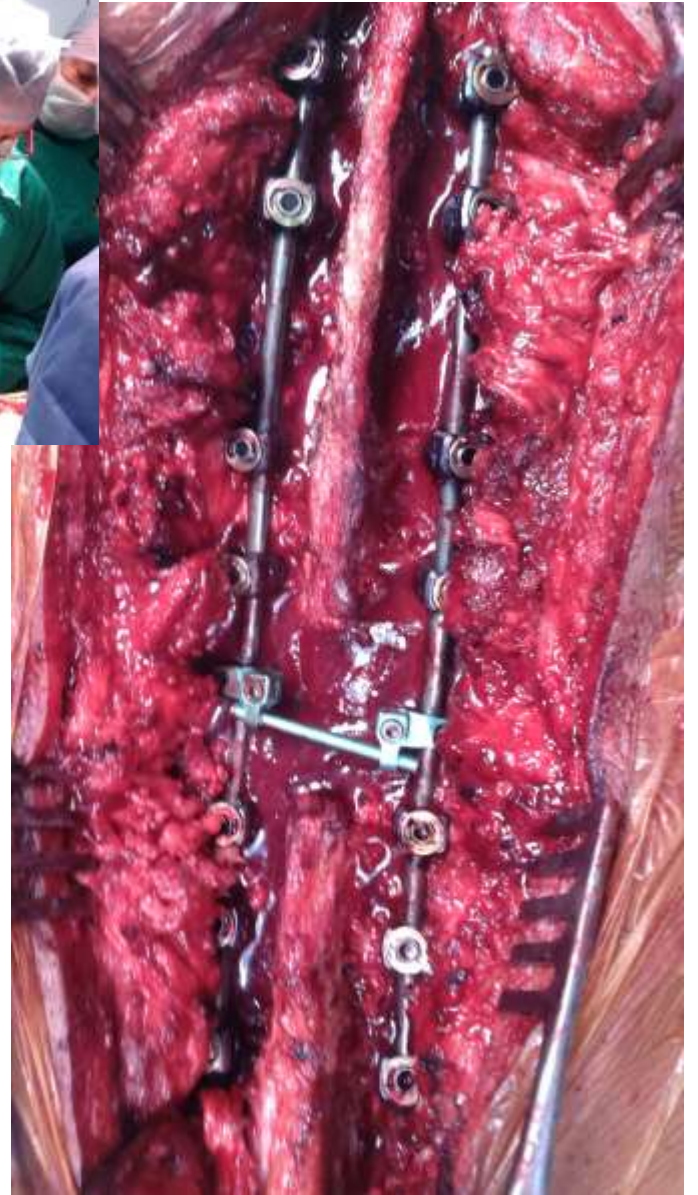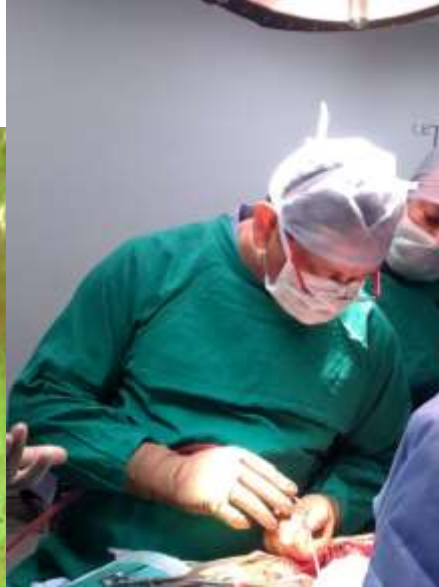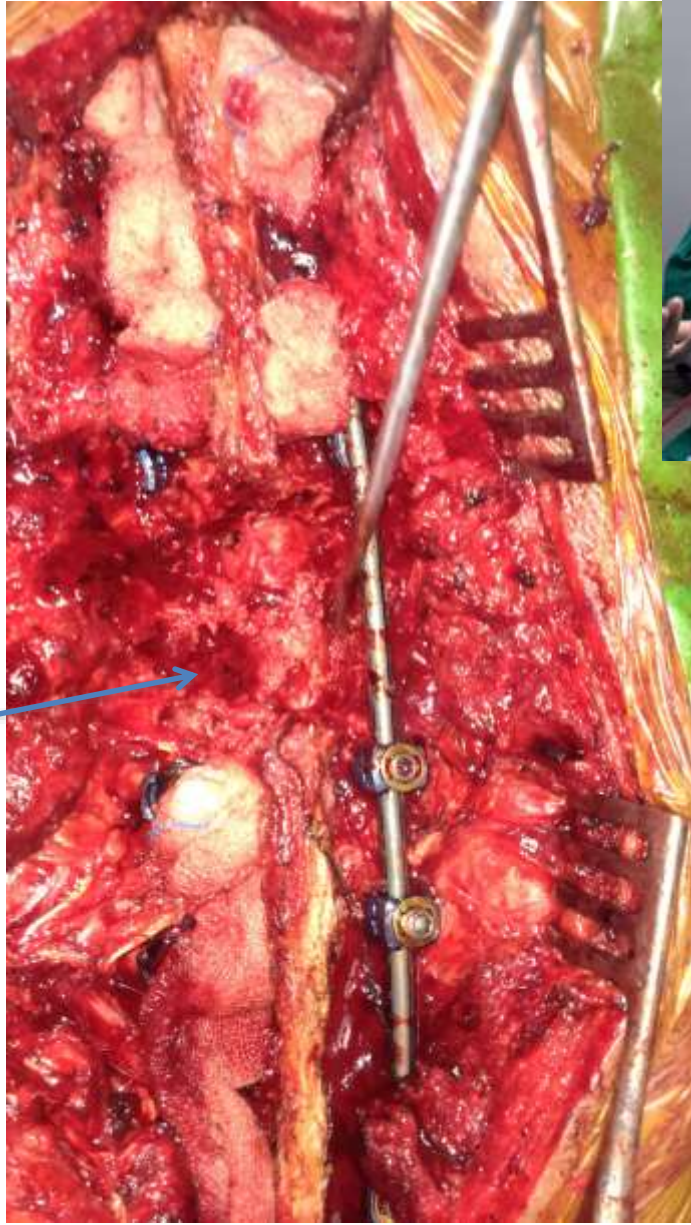
COMPLEX SPINE CASES IN KOLKATA - 2014

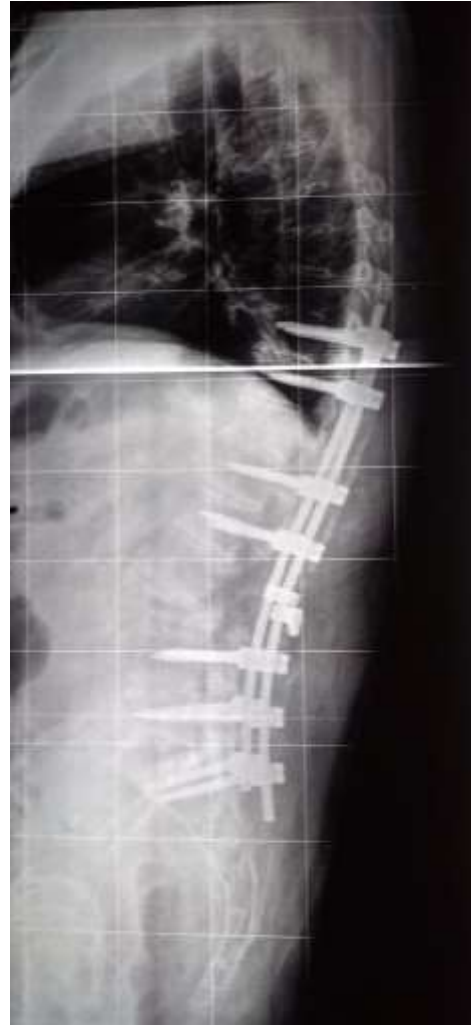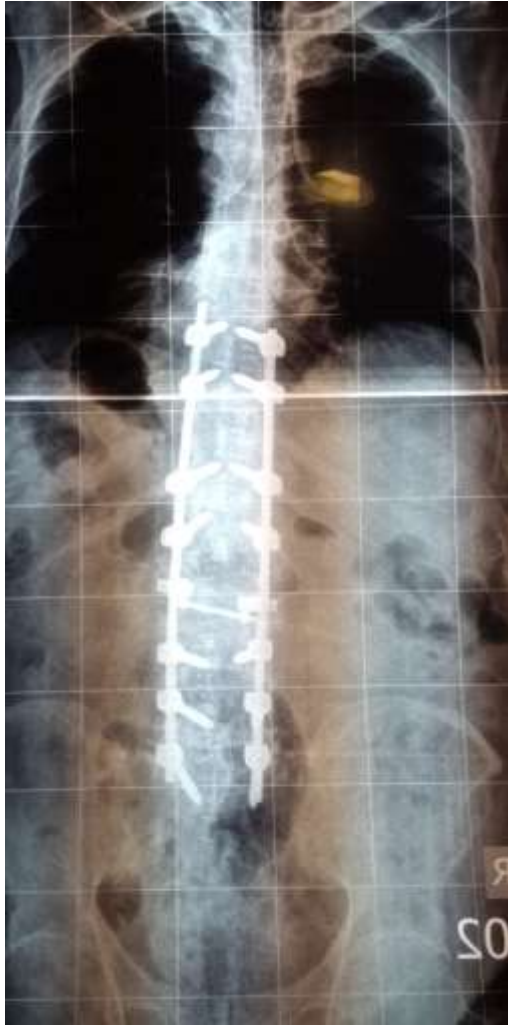Dr Ujjwal K Debnath,
Consultant Orthopaedics & Spine Surgeon

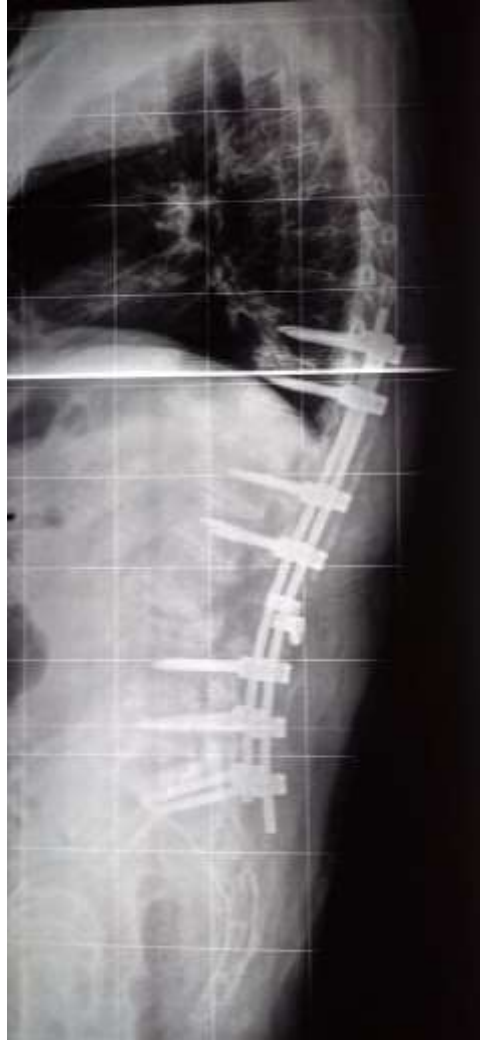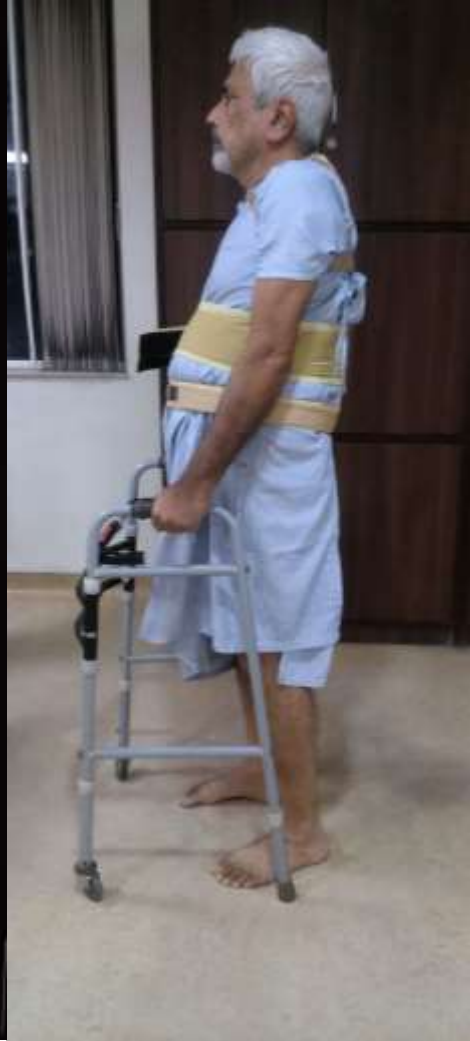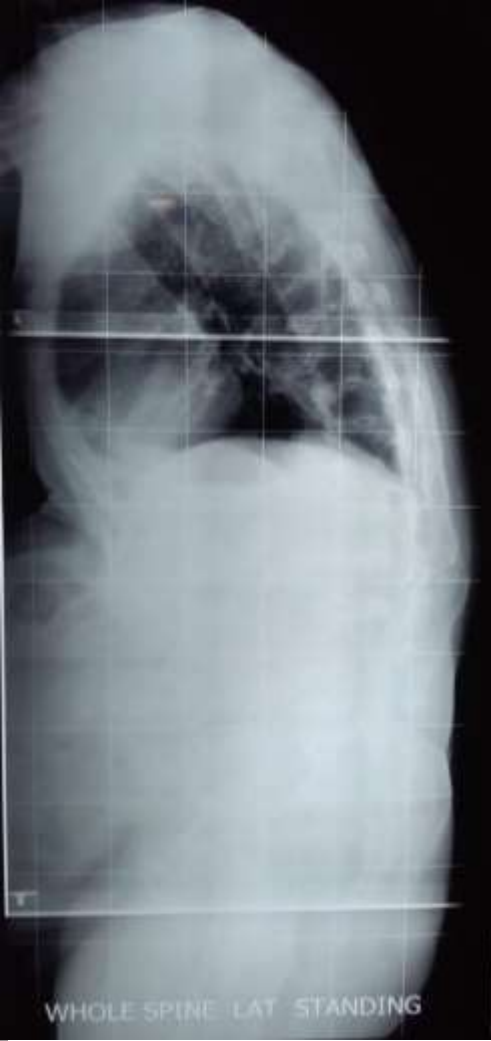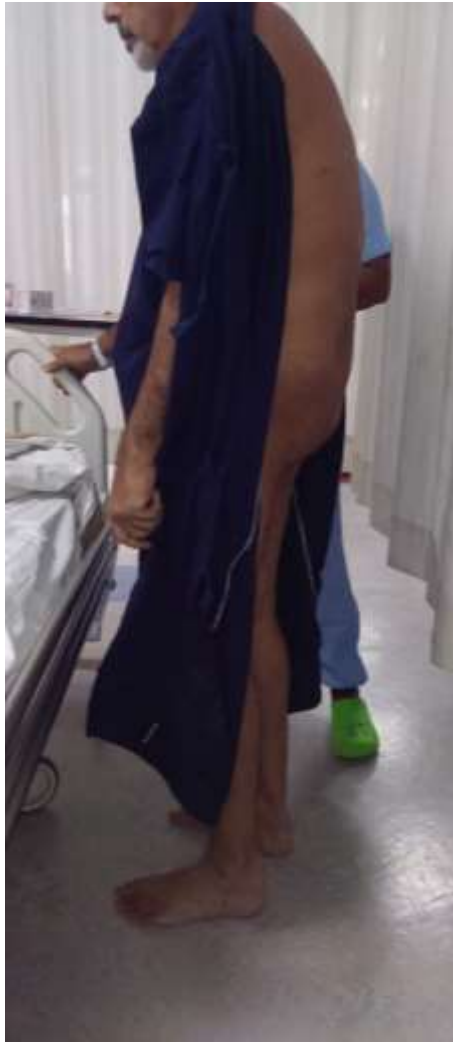62 Y Male G Bose , 2014, Smoker
Ank spond with L3 fracture



Consulted 3 months after fracture







52 y/M, Masai from Kenya, with
Multiple Myeloma and spinal foci at
multiple sites, T4, T7 and L5

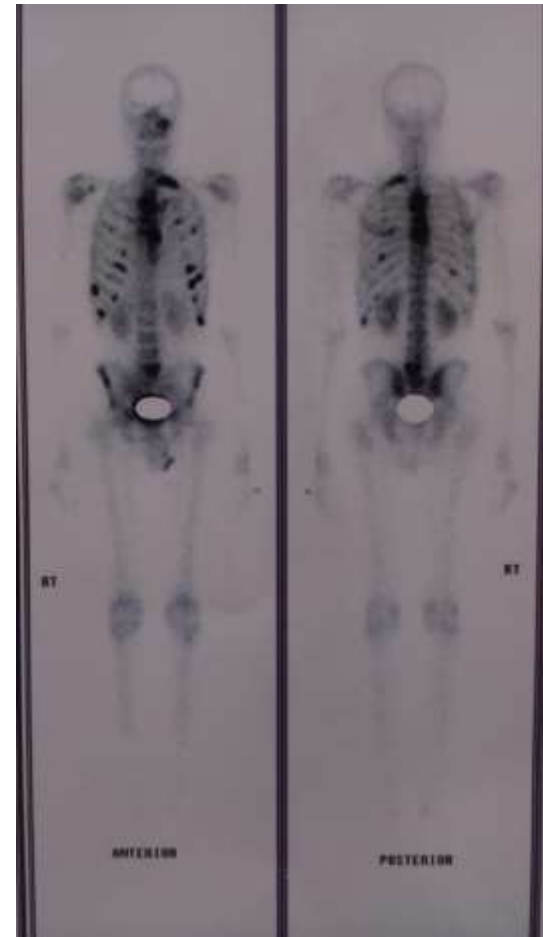
Rx: medically followed by surgically

Sx: Single stage

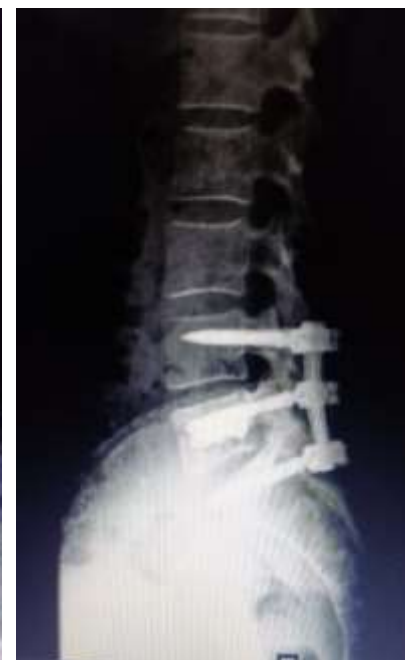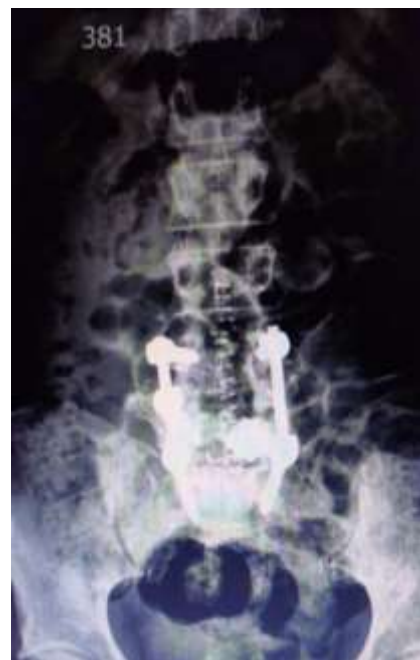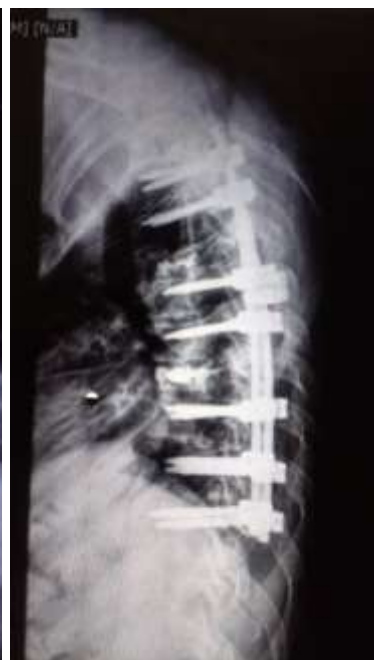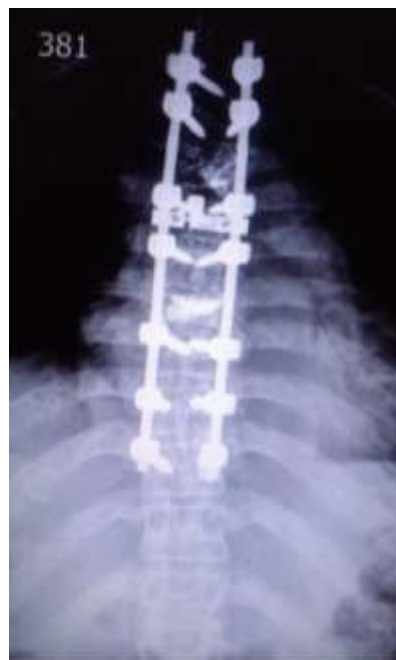Posterior instrumented fusion

T2 to T10 & L4 to S1

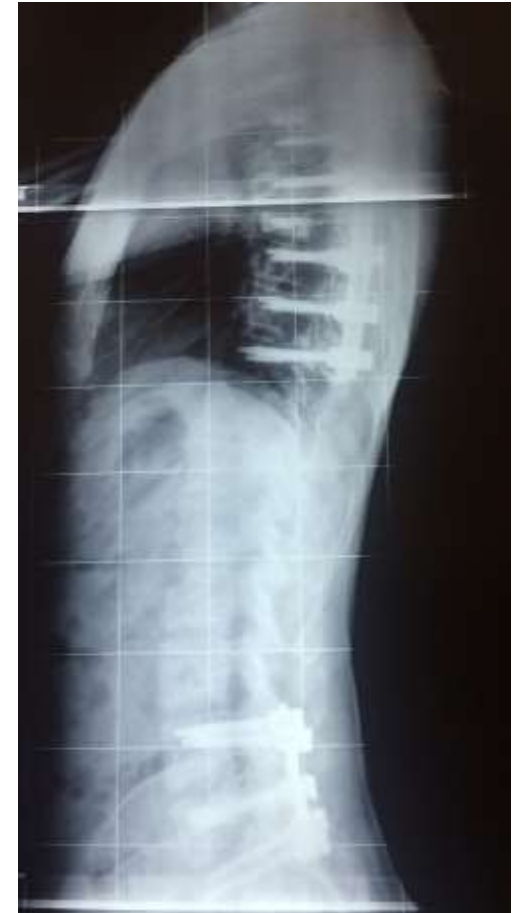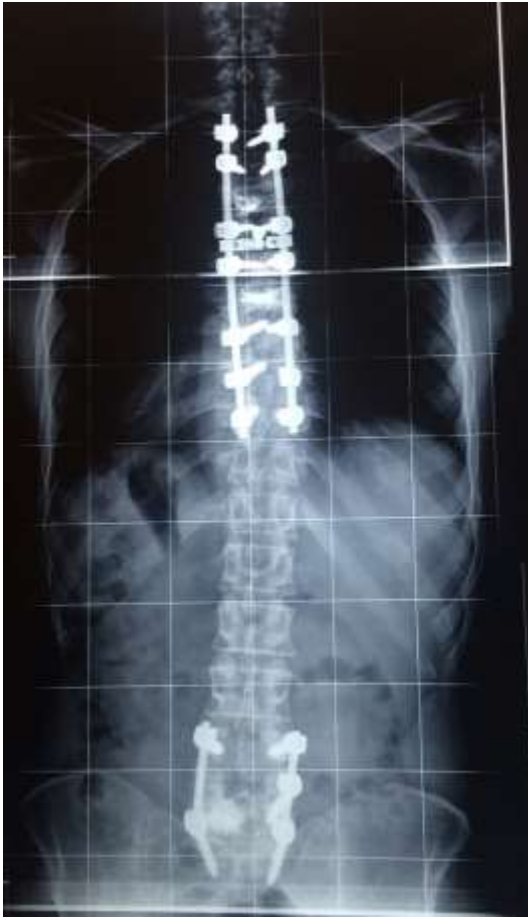with Kyphoplasty at T4, T7 and L5



5th post op day

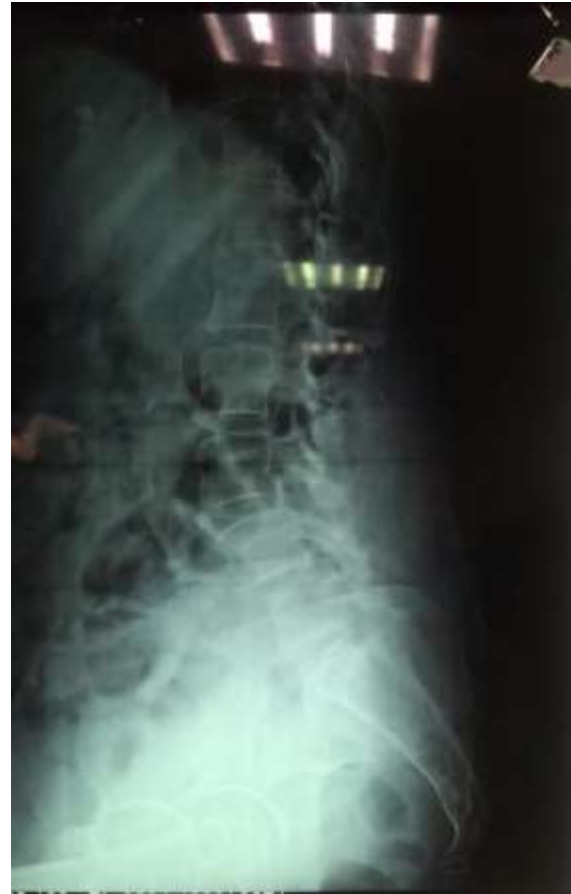
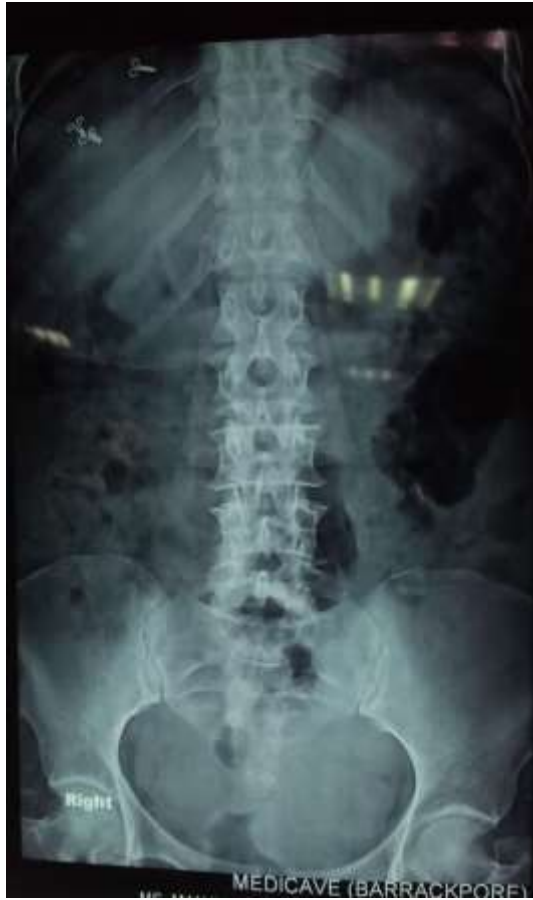
20mths post op – Peter doing well

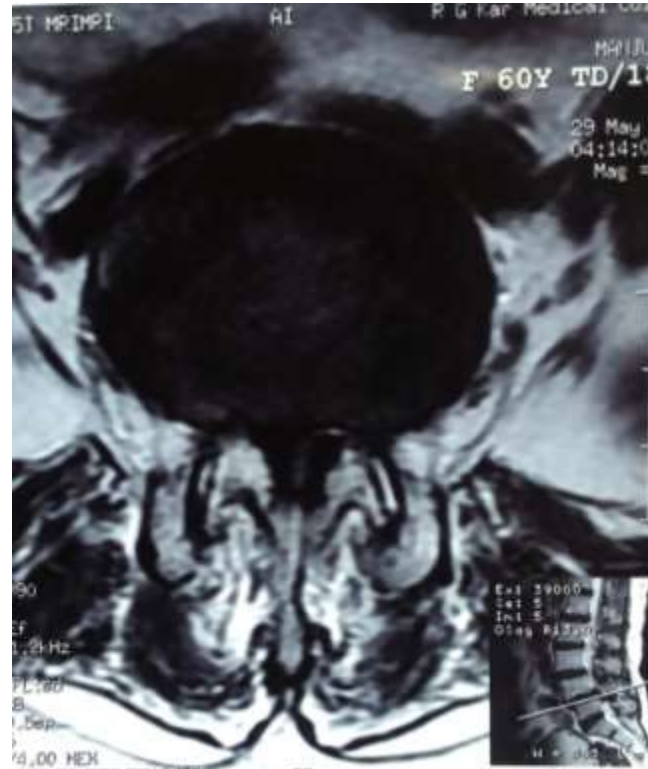
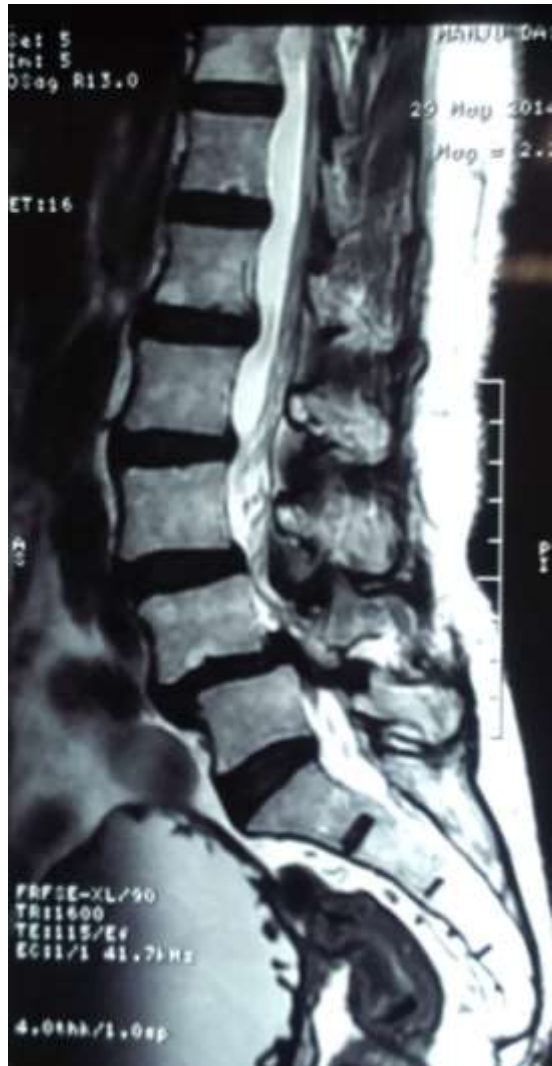
At my home in jul 2016 for dinner

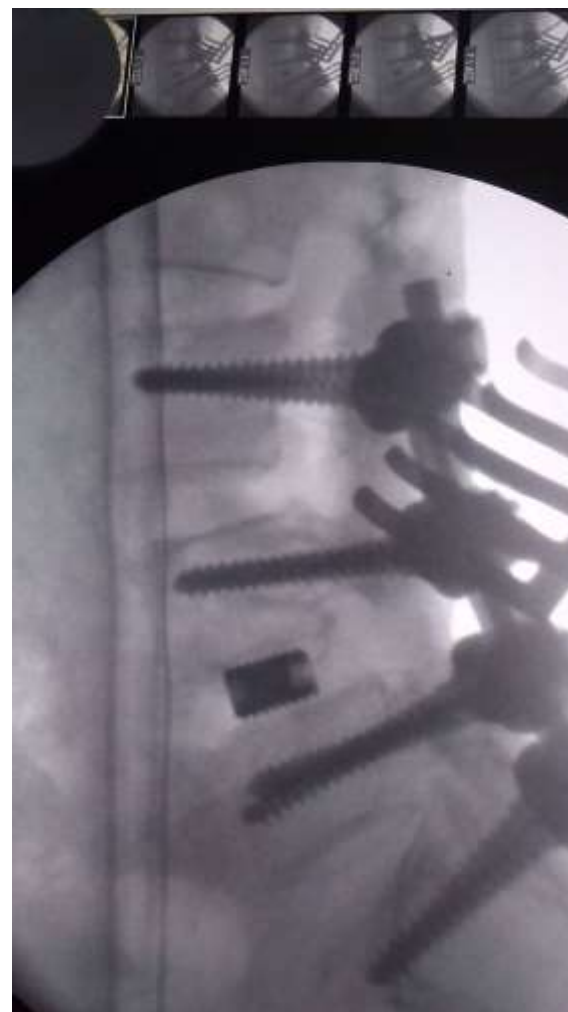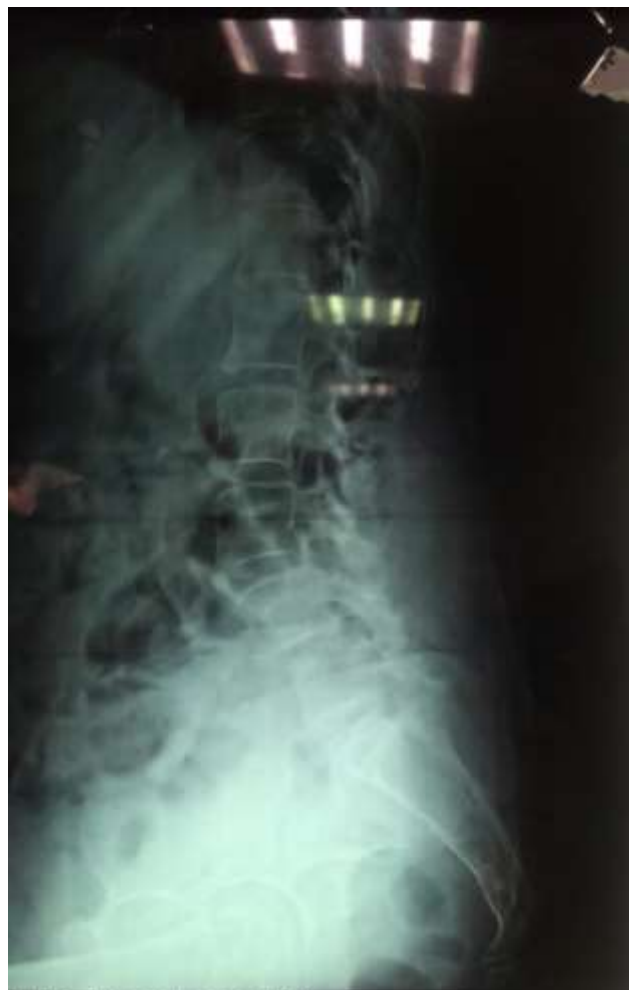52Y F, MD, severe Listhesis L4/5



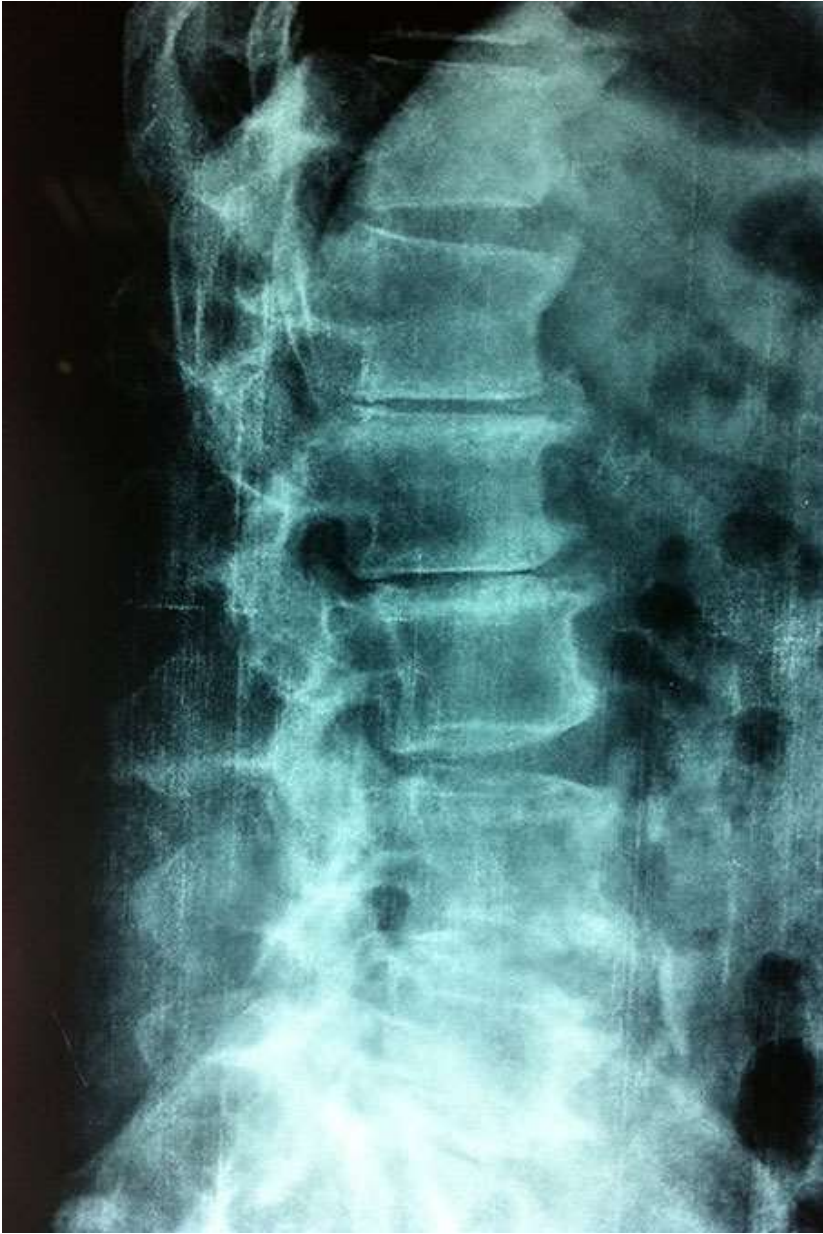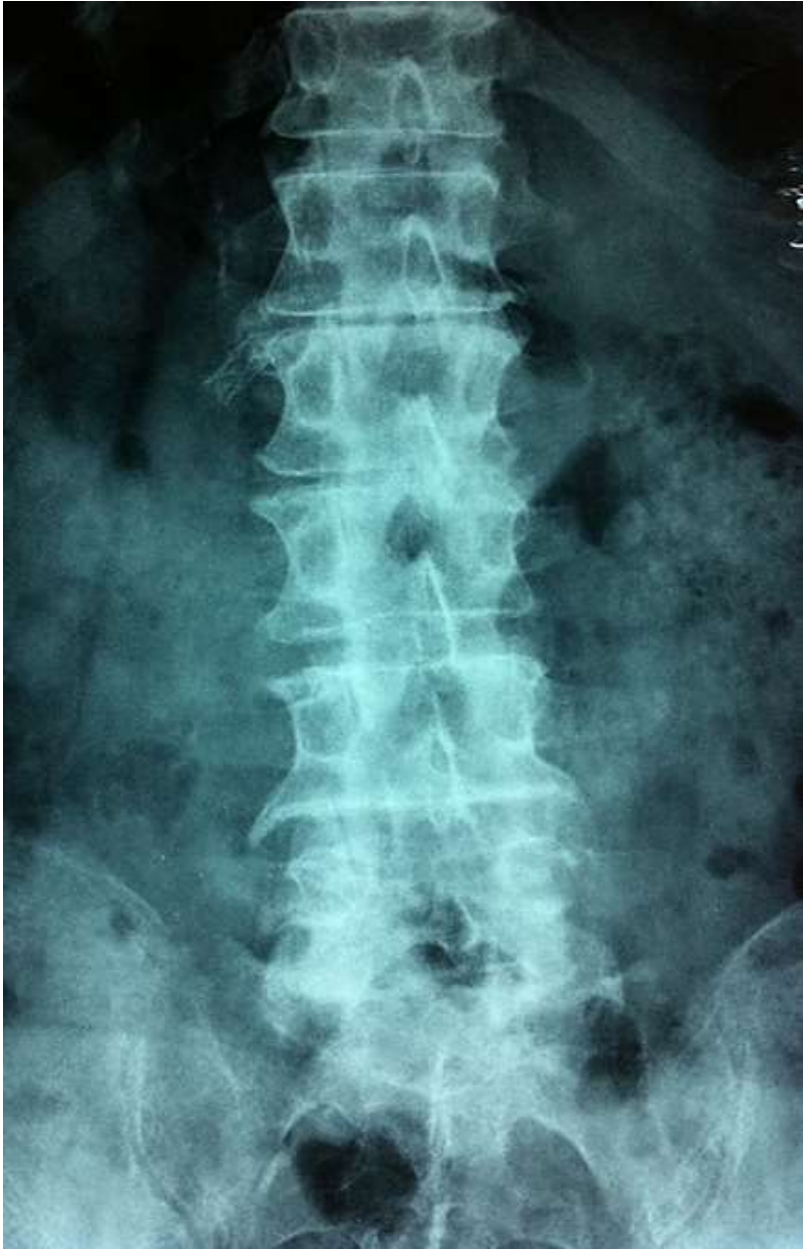MRI



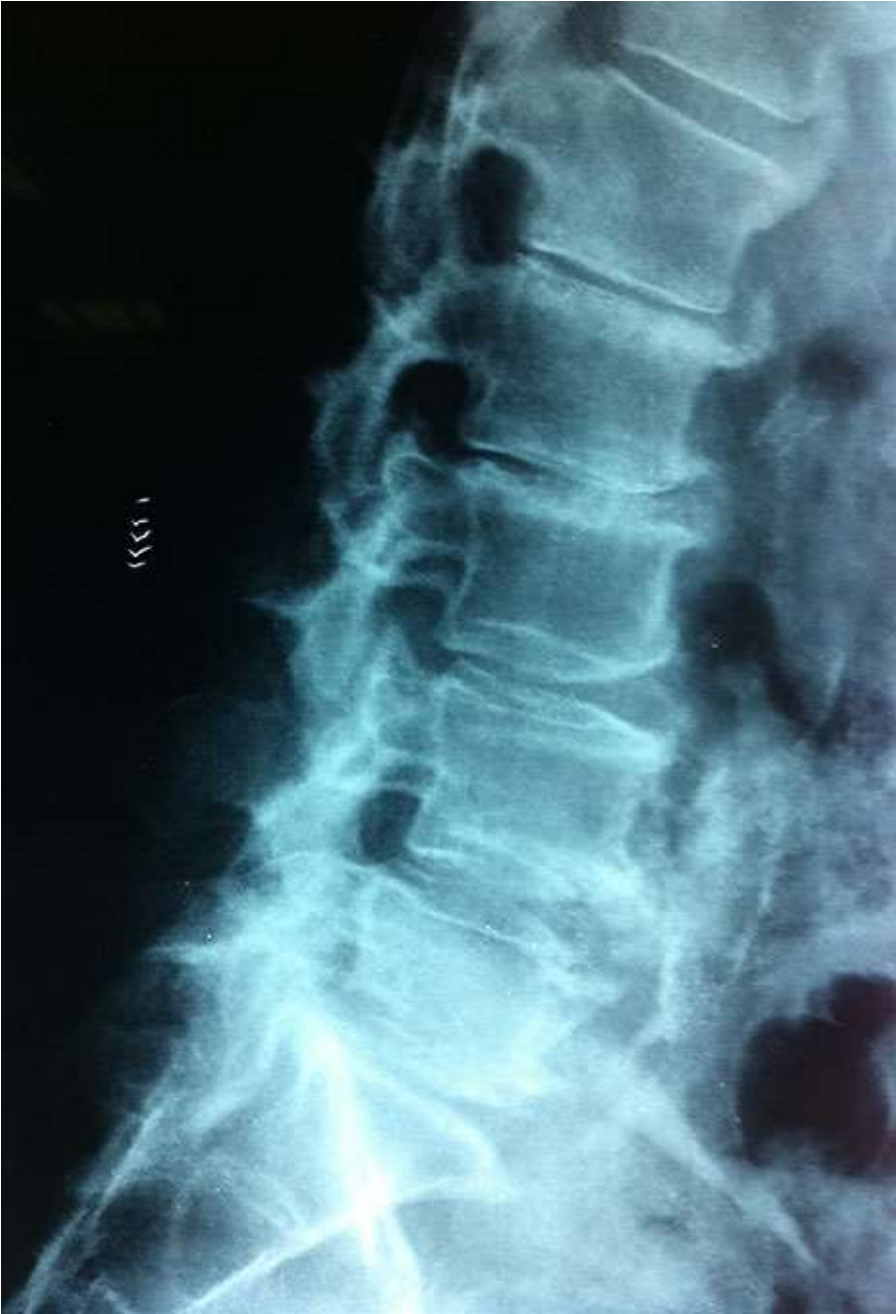INTRA OP XRAYS



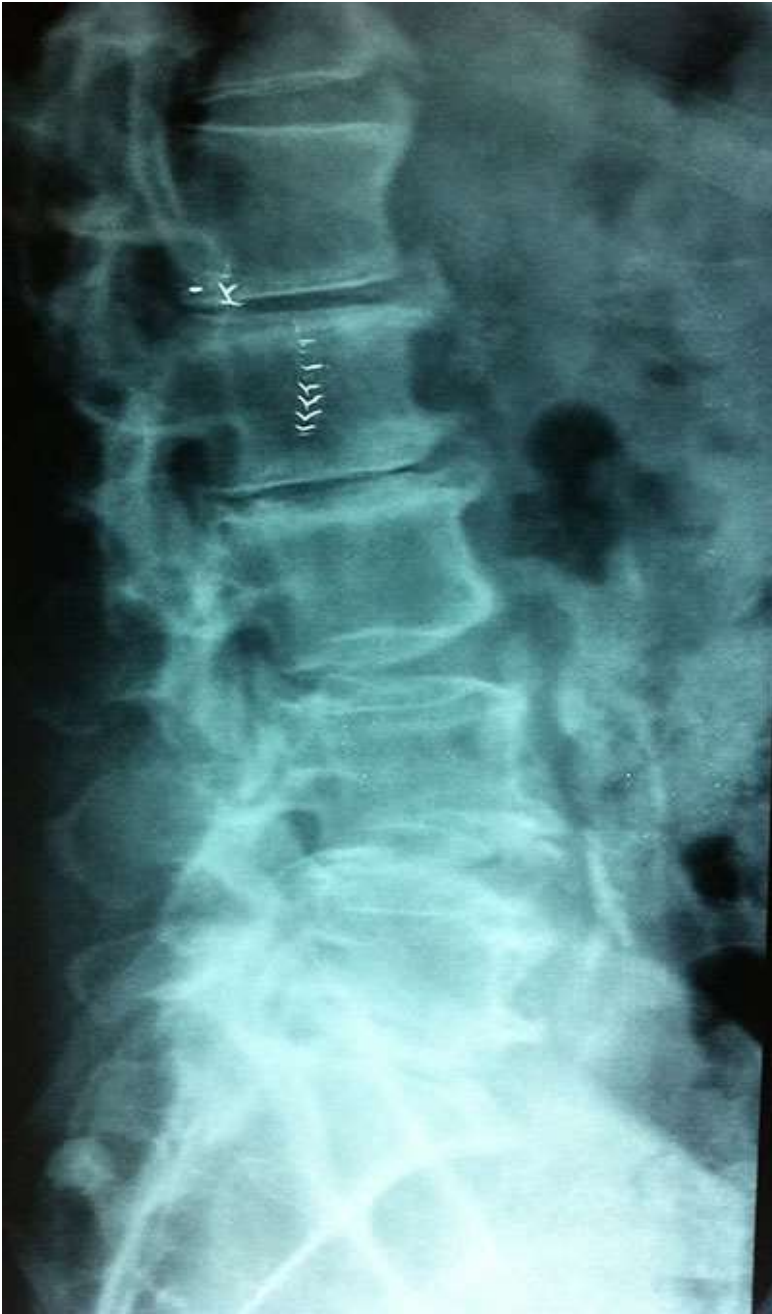65Y M, DG with severe upper lumbar L1, L2,3 stenosis with Sagittal imbalance



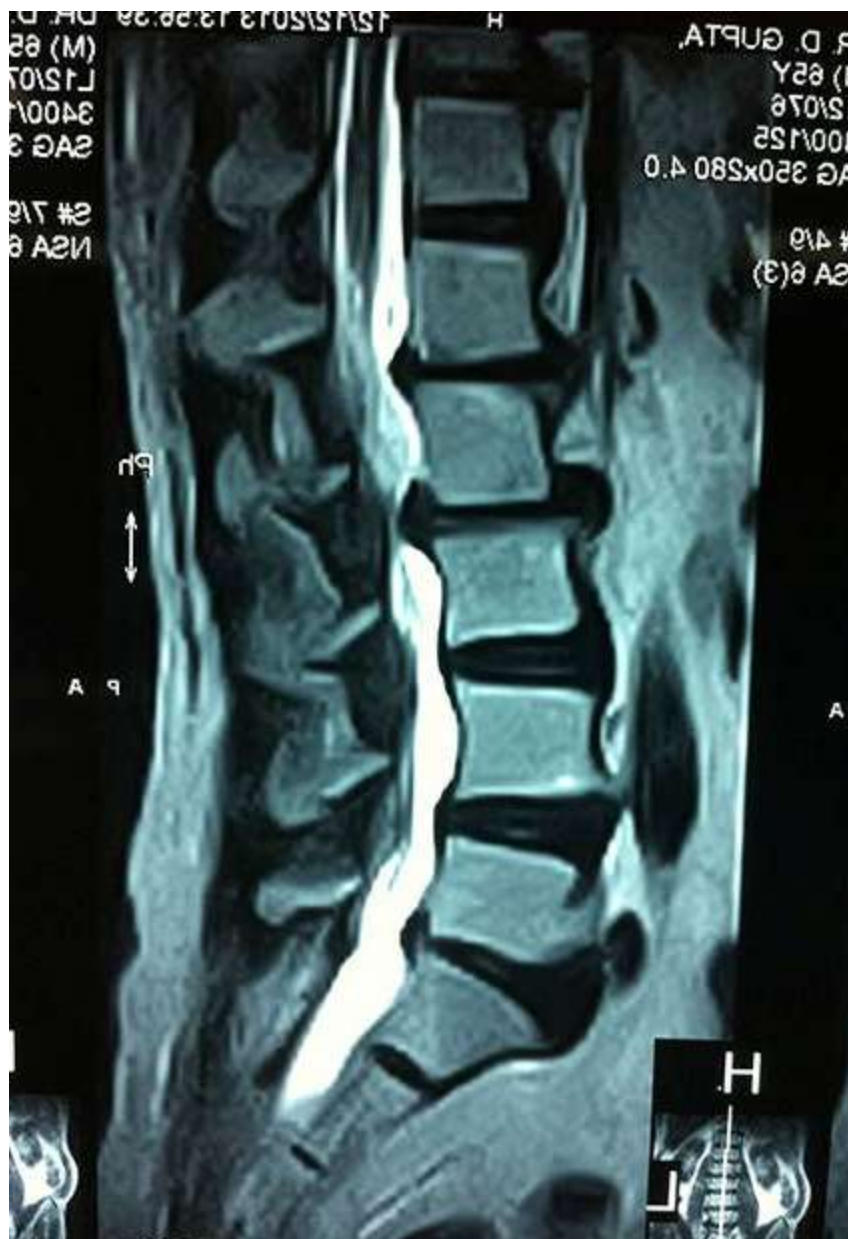FLEXION views



EXTENSION views



MRI



POST OP XRAYS

